

Zone III REBOA and the COBRA-OS™: Safety of Inadvertent Iliac Artery Device Deployment

Adam Power¹, Asha Parekh¹, Tyler Beveridge¹, Adam Groh¹
and Laura J Moore²

¹Western University, London, ON, Canada

²University of Texas McGovern Medical School, Houston, Texas, USA

Background: Resuscitative Endovascular Balloon Occlusion of the Aorta is an emerging technique in trauma. However, inadvertent iliac artery balloon inflation can lead to complications. This study aims to investigate the safety characteristics of the COBRA-OS™ compared with a 7-Fr commercially available device during purposeful iliac artery balloon overinflation.

Methods: In vitro: the COBRA-OS™ was inflated in explanted porcine iliac arteries and intentionally overinflated until balloon or vessel rupture occurred. In vivo: the COBRA-OS™ and 7-Fr device were deployed in the iliac arteries and intentionally overinflated until rupture of the balloon or blood vessel.

Results: In vitro: an average volume of 1 ml was required for occlusion using the COBRA-OS™ and the mean balloon rupture volume was 32.5 ml. The COBRA-OS™ partially migrated into the aorta in all cases. In vivo: the COBRA-OS™ and 7-Fr device occluded the iliac arteries with a mean volume of 3.5 ml. Overinflation resulted in no iliac ruptures with the COBRA-OS™ (mean balloon rupture volume = 10 ml). Overinflation with the 7-Fr device resulted in 1 iliac rupture at 5 ml. The other two 7-Fr devices had a mean balloon rupture volume of 5 ml. All COBRA-OS™ devices moved partially up into the aorta during inflation while all 7-Fr devices remained in the iliac artery.

Conclusions: The COBRA-OS™ allows for significant overinflation when deployed in the common iliac artery of a porcine model due to its unique design. This ultimately may help to prevent balloon and blood vessel rupture during clinical use; however, further studies are required.

Keywords: REBOA; Iliac; Safety

Received: 12 May 2021; Accepted: 18 May 2021

INTRODUCTION

Non-compressible torso hemorrhage (NCTH) can be temporized by the use of Resuscitative Endovascular Balloon Occlusion of the Aorta (REBOA) prior to

definitive management in the operating room [1]. Broadly speaking, REBOA is a minimally invasive procedure that entails introducing a balloon catheter through the femoral artery into the aorta, providing temporary aortic occlusion and a bridge to definitive surgical hemostasis. Aortic occlusion is normally intended for Zone I (left subclavian to the celiac artery) or Zone III (renal arteries to iliac bifurcation). The zone of deployment decision is generally based on the location of the injury and the hemodynamic status of the patient [2].

There are a number of known complications associated with the use of REBOA [3]. One complication that may arise with Zone III occlusion is the inadvertent deployment of the REBOA device in the iliac artery instead of the intended infrarenal aorta, which can lead to iliac artery rupture or ineffective aortic occlusion. This complication is mainly due to the relatively short

Corresponding author:

Adam Power MD, Western University, Victoria Hospital, Room E2 121,
800 Commissioners Road East, London, ON, Canada, N6A 5W9.

Email: adam.power@lhsc.on.ca

Presentation: A portion of the data from this study was presented at the Trauma Association of Canada (TAC) 2021 Annual Meeting, which took place virtually from April 12-16, 2021.

© 2021 CC BY 4.0 – in cooperation with Depts. of Cardiothoracic/
Vascular Surgery, General Surgery and Anesthesia, Örebro
University Hospital and Örebro University, Sweden

length of Zone III (median 8.7 cm) [4] and the clinical desire to stay below the renal arteries to avoid Zone II deployment (para-visceral occlusion) with the inherent risk of mesenteric and renal ischemia, especially during prolonged inflation times [3]. It can also happen when the device is cycled through inflation and deflation, with subsequent distal migration of the device.

The COBRA-OS™ is a novel 4-Fr REBOA device [5] that has been designed to provide an increased safety profile, including: (1) the ability to tolerate significant overinflation; and (2) the propensity for retrograde migration into the aorta in the case of inadvertent iliac artery deployment. This study investigates these safety characteristics using an in vitro porcine model and further examines them in a comparative study with a commercially available 7-Fr REBOA device in an in vivo porcine model.

METHODS

The COBRA-OS™

The device used for aortic occlusion in this study was the COBRA-OS™ (see Figure 1). The COBRA-OS™ is a large vessel balloon occlusion system designed to be inserted through a 4-Fr sheath. A 4-Fr Custom Sheath Introducer Kit (0.018-inch guidewire) that accompanies the device is used to gain access to the common femoral artery in the groin. The COBRA-OS™ is designed to

occlude the aorta in the descending thoracic aorta (Zone 1; solid black marker; indicating 48-cm depth) or to occlude the aorta below the renal arteries (Zone 3; three black markers; indicating 28-cm depth). Its overall working length and therefore maximal reach is 55 cm. The device consists of a stiff stainless-steel inner guidewire with an atraumatic floppy distal J-tip that is housed in a compliant occlusion balloon with proximal and distal necks. The balloon is off-set upwards towards the J-tip and has a maximum diameter of 25 mm. No other guidewires are required and this is not an over-the-wire device. A reusable J-tip straightener is preloaded on the distal neck to facilitate the introduction of the device into the 4-Fr introducer sheath hemostasis valve. There is no arterial line monitor associated with the device. There is a unique Safety Shoulder Reservoir™ that was designed to allow the balloon to preferentially grow in length once the balloon has reached full occlusion instead of continued diameter increase. This is meant to help prevent rupture of the balloon or vessel by off-loading the additional inflation volume into the “reservoir”.

In Vitro

Three explanted porcine aortas with attached iliac arteries were obtained from a local abattoir (Mount Brydges Abattoir, Mount Brydges, ON, Canada). Testing was performed using the COBRA-OS™ (Front Line Medical Technologies Inc., London, ON, Canada) on fresh and untreated tissue.

A total of three iliac arteries were deemed viable for testing based on visual inspection. Baseline diameter and length measurements of the usable iliac arteries were recorded. The COBRA-OS™ was inserted through the lumen of the artery and inflated with saline until vessel occlusion occurred based on direct visualization. We ensured that the point of maximum diameter of the balloon was centered along the entire length of the iliac artery (including external and common iliac artery). Saline was then continuously injected to observe the device response to overinflation and volume was monitored until either rupture of the balloon or blood vessel was observed. The position and location of the balloon were also monitored and documented for any migration. Upon rupture of the balloon or artery, the vessels were opened to expose the intima at the treated site. The device was removed and discarded in order to enable assessment for damage where the balloon was inflated. The vessel was inspected both internally and externally to assess for any macroscopic arterial damage and photographic images were taken.

In Vivo

Under an animal use protocol obtained from Western University, three adult female pigs with a mean weight

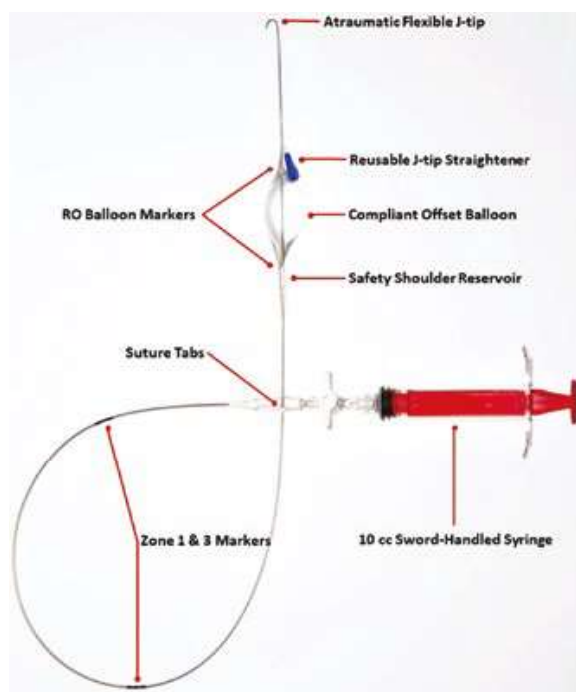


Figure 1 Image of the COBRA-OS™ with syringe attached and features labelled. RO, radiopaque.

of 67 kg were tested in this study, enabling the use of six iliac arteries in total. One device was deployed per iliac artery: three using the COBRA-OS™ and three using a commercially available 7-Fr device.

Under ultrasound guidance, a 4-Fr introducer sheath was placed in the left common femoral artery percutaneously for introduction of the COBRA-OS™ and a 7-Fr introducer sheath was placed in the right common femoral artery for introduction of the 7-Fr device. A lower midline incision was performed to expose both iliac arteries and the aorta for visualization. Both devices were advanced into the common iliac arteries, which was confirmed by direct arterial palpation and visualization of radiopaque marker bands of the devices under X-ray guidance. We ensured that the points of maximum diameter of both test devices were centered along the length of the common iliac artery. Note that, because of this, the safety shoulder reservoir of the COBRA-OS™ was partially contained within the 4-Fr sheath due to the porcine anatomy. The devices were inflated with saline consecutively until vessel occlusion occurred based on loss of arterial pulse below the devices. Volume was recorded and inflation was continued to intentionally overinflate the balloon until either rupture of the balloon or blood vessel occurred. The position and location of the balloon were also monitored and documented for any migration and X-ray images were taken. Upon rupture of the balloon or artery, the vessels were opened to expose the intima at the treated sites and were inspected both internally and externally to assess for any macroscopic arterial damage.

The primary endpoints of this study were rupture of the balloon or blood vessel and the final position of the balloon in the vessel.

Ethical Approval and Informed Consent

As this was an animal study, no research ethics board approval was required.

RESULTS

In Vitro

A total of three iliac arteries were used in this in vitro study, with a mean common iliac diameter of 10 mm and mean length of 7.7 mm. All testing resulted in balloon rupture and no occurrence of iliac rupture. An average volume of 1 ml was required to occlude the artery using the COBRA-OS™ and the mean balloon rupture volume with overinflation was 32.5 ml (see Figure 2a). The COBRA-OS™ partially migrated into the aorta in all three cases and migration occurred at an average inflation volume of 15 ml. Visual inspection and photographic images showed no evidence of gross arterial damage at the treatment sites (see Figure 2b).

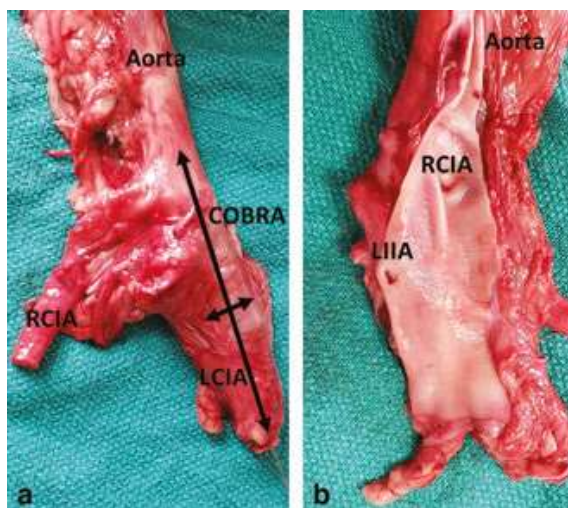


Figure 2 In vitro images. (a) In vitro deployment of COBRA-OS™ (COBRA) in left common iliac artery (LCIA) with migration into aorta and subsequent occlusion of right common iliac artery (RCIA). (b) Left common iliac artery and aorta opened up post-rupture of COBRA-OS™ with right common iliac artery (RCIA) and left internal iliac artery (LIIA) orifices shown and no intimal damage seen.

In Vivo

A total of six iliac arteries were used in this in vivo study, with a mean common iliac diameter of 7.7 mm on the left and 7.3 mm on the right. Both the COBRA-OS™ and the 7-Fr device occluded the common iliac artery with a mean volume of 3.5 ml (range 3–4 ml). Overinflation in the COBRA-OS™ resulted in three balloon ruptures at a mean balloon rupture volume of 10 ml (range 9–11 ml, 280% overinflation) and no iliac ruptures. Overinflation with the 7-Fr device resulted in two balloon ruptures with a mean balloon rupture volume of 5 ml (40% overinflation) and one iliac rupture at 5 ml. All COBRA-OS™ devices moved partially up into the aorta during inflation (after the maximum diameter of the balloon was centered along the length of the common iliac artery), while all 7-Fr devices remained in the common iliac artery, as shown by X-ray images. Figure 3 shows both devices deployed simultaneously for demonstration purposes. Visual inspection showed no evidence of gross arterial damage at the treatment sites in the non-ruptured iliac arteries.

DISCUSSION

The benefits of REBOA in NCTH as a surgical adjunct are offset by the potential complications of the technique and devices used. Blind insertion and inflation are often necessary, which can increase these risks further [6]. Improving the safety of REBOA is important in reducing

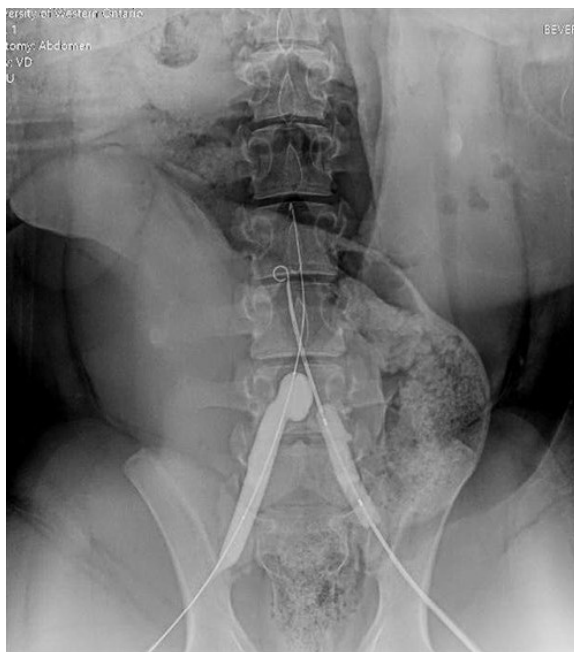

Figure 3 COBRA-OS™ deployed in the right iliac artery with migration into the aorta; 7-Fr device deployed in the left iliac artery.

the associated risks but also to increase the overall adoption of this potentially life-saving tool.

This study evaluates the behavior of the COBRA-OS™ during inadvertent iliac artery deployment in a pig model. The potential increased safety can primarily be attributed to both the off-set eccentric shape of the balloon and secondarily due to its Safety Shoulder Reservoir™. During over-inflation of the COBRA-OS™ with intentional iliac artery positioning and deployment in this study, the off-set nature of the balloon made it grow “upwards” towards the aortic bifurcation and allowed for the balloon to migrate into the aorta once the point of maximum diameter of the balloon rose above the bifurcation, with a “water-melon seeding” effect. The provision for the COBRA-OS™ to migrate preferentially into a larger space of the aorta may seem intuitive and inevitable; however, we have demonstrated that this is not an intrinsic feature of all devices. The design of the COBRA-OS™ facilitates and allows for this migration to occur, potentially decreasing the risk of vessel rupture. During this study, it proved difficult to keep the COBRA-OS™ balloon in the iliac artery to test rupture, and physical retraction had to be employed to obtain correct rupture data. There are scenarios beyond iliac artery deployment in which this safety characteristic could be potentially useful. For example, if the COBRA-OS™ was theoretically deployed from the brachial artery, the same principles would apply to the sub-clavian artery.




Figure 4 COBRA-OS™ with full occlusion in a stiff plastic 13-mm tube on the left and two subsequent overinflation images for demonstration purposes of the Safety Shoulder Reservoir™. The length of the balloon on the far right is approximately 10 cm.

The ability of the COBRA-OS™ to sustain overinflation is due to the compliant nature of its balloon material and its unique Safety Shoulder Reservoir™. This unique reservoir allows for preferential longitudinal growth once occlusion has occurred as opposed to increased radial pressure being applied to the artery. The compliant balloon material can expand up to approximately 10 cm in length, with the superior 5 cm being the functional balloon occlusion region and the inferior 5 cm being the tapered shoulder reservoir region (see Figure 4). These safety characteristics are more pronounced in a porcine model, representing an extreme case of the small arterial sizes that may be seen in an adult patient population. The COBRA-OS™ has been shown in our study to possess significant overinflation capabilities even in these exaggerated circumstances with no incidence of arterial rupture despite intentional overinflation.

The significantly smaller overinflation volumes of the in vivo study versus the in vitro study are likely due to the fact that the safety shoulder reservoir was partially contained within the 4-Fr sheath in the in vitro study. If the three black markers (indicating Zone 3) are used in practice and positioned at the 4-Fr sheath valve, then no part of the safety shoulder reservoir would be contained within the sheath.

The limitations of this study included a small sample size and the potential for human error with visual measurements. We are also unable to determine if the same results would be applicable to human arterial anatomy.

In conclusion, the COBRA-OS™ possesses unique safety characteristics that allow for significant overinflation and safe migration into the aorta when inadvertently deployed in the common iliac artery of a porcine model. Further studies are required, but this study demonstrates that the COBRA-OS™ may help prevent balloon and iliac artery rupture during clinical use.

Ethics Statement

- (1) All the authors mentioned in the manuscript have agreed to authorship, read and approved the manuscript, and given consent for submission and subsequent publication of the manuscript.
- (2) The authors declare that they have read and abided by the JEVTM statement of ethical standards including rules of informed consent and ethical committee approval as stated in the article.

Conflicts of Interest

A Power and A Parekh are co-founders and have an equity stake in Front Line Medical Technologies Inc. LJM is Chair of the Scientific Advisory board, has an equity stake, and receives consulting fees from Front Line Medical Technologies Inc.

Funding

This study was generously funded by Western University's Department of Surgery Internal Research Fund 2019.

Author Contributions

A Power and A Parekh were involved in the study design. A Power, A Parekh, TB, and AG were involved in

data collection. All authors were involved in data analysis, data interpretation, and critical revisions.

REFERENCES

- [1] Moore LJ, Fox EE, Meyer DE, et al. Prospective observational evaluation of the ER-REBOA catheter at 6 U.S. trauma centers. *Ann Surg.* 2020; *In Press.* doi: 10.1097/SLA.0000000000004055.
- [2] Johnson NL, Wade CE, Fox EE, et al. Emergent truncal hemorrhage control study group. Determination of optimal deployment strategy for REBOA in patients with non-compressible hemorrhage below the diaphragm. *Trauma Surg Acute Care Open.* 2021;6(1):e000660.
- [3] Davidson AJ, Russo RM, Reva VA, et al; BEST Study Group. The pitfalls of resuscitative endovascular balloon occlusion of the aorta: Risk factors and mitigation strategies. *J Trauma Acute Care Surg.* 2018;84(1):192–202.
- [4] Eliason JL, Derstine BA, Horbal SR, et al. Computed tomography correlation of skeletal landmarks and vascular anatomy in civilian adult trauma patients: Implications for resuscitative endovascular balloon occlusion of the aorta. *J Trauma Acute Care Surg.* 2019;87(1S Suppl 1):S138–S145.
- [5] Power A, Parekh A, Scallan O, et al. Size matters: first-in-human study of a novel 4 French REBOA device. *Trauma Surg Acute Care Open.* 2021;6(1):e000617.
- [6] Wasicek PJ, Teeter WA, Brenner ML, Hoehn MR, Scalea TM, Morrison JJ. Resuscitative endovascular balloon occlusion of the aorta: rupture risk and implications for blind inflation. *Trauma Surg Acute Care Open.* 2018;3(1):e000141.